

Evaluation of treatment of hereditary rickets in Egyptian children

Mona Aglan¹, Mona M. Ibrahim², M. Elnashar³, Samia A. Temtamy¹, Ghada A. Otaify¹

¹Clinical Genetics and ²Biochemical Genetics Departments, National Research Centre, Cairo, Egypt, ³Medical Studies Department, Institute of Postgraduate Childhood Studies, Ain Shams University

Abstract

Background: Rickets is the clinical consequence of impaired mineralization of bone matrix throughout the growing skeleton. Rickets is one of the most common non-communicable diseases of children in the developing world (Craviari et al., 2008). Although nutritional rickets is the most common type of this disease, there are several other forms, including genetic disorders of vitamin D metabolism or phosphate transport. Although rare, hereditary hypophosphataemic rickets is the most common form of heritable rickets (Caetano et al., 2012).

Patients and Methods: This descriptive and prospective study included 13 Egyptian children with hereditary rickets who were recruited from the Limb Malformations and Skeletal Dysplasia Clinic, National Research Centre from January 2010 to December 2012. They were classified into calcipenic and phosphopenic rickets according to basal calcium and phosphorous serum levels and received medications accordingly.

Results: Thirteen children with hereditary rickets were studied, with a median age at presentation of 3 years (IQR 2.0- 4.3) four of which were calcipenic (30.8%) and nine cases were hypophosphatemic rickets (69.2%). All patients had bone deformities mainly bowing of legs with genu valgum, bony pain and broad wrists and ankles. Growth retardation was present in all patients except two with hypophosphatemic rickets. One patient of calcipenic rickets showed clinical and laboratory improvement thus suggesting the diagnosis of 1 α -Hydroxylase Deficiency, however the other 3 patients were resistant to treatment and one of them had alopecia totalis with the most severe clinical phenotype indicating the diagnosis of hereditary vitamin D-resistant rickets (HVDRR). Nine patients had hypophosphatemic rickets. They were treated with calcitriol at a dose of 0.5 μ /kg/day and oral phosphorous. Improvement in bony pains and rachitic manifestations was noted but no improvement was detected in growth in the short cases. Two patients developed secondary hyperparathyroidism due to overtreatment with phosphorous.

Conclusion: Hereditary rickets comprise a rare group of metabolic bone disorders with significant long-term morbidity. They should be suspected in children presenting with short stature, developmental delay and orthopedic abnormalities with increased alkaline phosphatase, low serum phosphorus or calcium which confirm the diagnosis. Early diagnosis and treatment are essential to minimize morbidity in children.

Keywords: Hereditary rickets- Calcipenic- Hypophosphatemic-Vitamin D- Children.

تقييم معالجة امراض لين العظام الوراثية لدى الأطفال المصريين

المقدمة: يشكل العظم الدعامة الهيكلية الداخلية لجسم الإنسان ويتكون من بروتين الكولاجين الذي يمد العظام بالقوة بالإضافة الى الكالسيوم والفوسفات الذي يزيد من صلابة النسيج العظمي. ينظم عملية ترسيب الكالسيوم بالعظام أو انطلاقه بالدم النشاط الهرموني والفيتامينات وحاجة الجسم للكالسيوم سواء بالدم أو العظام. ويلعب فيتامين د دوراً هاماً في امتصاص الكالسيوم في الجهاز الهضمي والكلية وحمله بالدم. وتعتبر أمراض لين العظام الوراثية أحد أهم اضطرابات العظام الأيضية الناتجة عن نقص ترسيب الكالسيوم والفوسفات بالعظام والغضاريف.

الهدف: تشخيص أمراض لين العظام الوراثية وتقييم آثار العلاج الدوائي المتاح خلال فترة ١٨ شهراً.

طرق وادوات الدراسة: يشكل هذا البحث دراسة وصفية واستطلاعية شملت الأطفال الذين يعانون من لين العظام الوراثي من المترددين على عيادة تشوهات العظام والأطراف الوراثية بالمركز القومي للبحوث في الفترة من يناير ٢٠١٠ الى ديسمبر ٢٠١٢. وتضمنت الدراسة ثلاث عشرة حالة وقد تم تصنيفهم الى لين عظام نتيجة نقص الكالسيوم ولين عظام نتيجة نقص الفوسفور وتم اعطاء العلاج تبعاً لكل سبب على حدة.

النتائج: وقد تضمنت الدراسة عدد ثلاث عشرة حالة من أمراض لين العظام الوراثي منهم أربع حالات نتيجة عيوب أيضية في عمل فيتامين د وقد تم علاجهم بجراحات عالية من الكالسيوم وفيتامين د النشط (وان ألفا) وقد كانت الإستجابة ضعيفة في ثلاثة منهم وجيدة في حالة واحدة فقط كما شمل البحث عدد تسع حالات نتيجة نقص الفوسفات وقد تم علاجهم باستخدام مركبات الفوسفات وفيتامين د النشط وقد اظهروا استجابة متفاوتة حيث تحسنت مظاهر لين العظام وتحسنت الآلام لكن لم يحدث تحسن في معدلات النمو والطول.

الخلاصة: بينت هذه الدراسة أهمية التشخيص المبكر لأمراض لين العظام الأيضية الوراثية وينبغي أن يشتبه في الأطفال في حالة وجود تأخر في النمو وتشوهات العظام مع ارتفاع مستوى الألكالين فوسفاتاز مع نقص في الفوسفور أو الكالسيوم. كما أكدت على ضرورة علاجها من قبل المتخصصين وذلك قبل حدوث تشوهات عظمية يصعب علاجها أو تحتاج لتدخل جراحى.

Introduction:

Rickets is the clinical consequence of impaired mineralization of matrix throughout a growing skeleton. Infants, children and adolescents can be affected. Osteomalacia results from this disturbance after growth plates fuse (i. e. adulthood) (Whyte and Thakker, 2013).

The major problems of rickets in childhood are growth retardation and bone deformity. In contrast, adult patients with osteomalacia present with muscle weakness and bone pain (Sahay& Sahay, 2013). Lower limb deformities such as bow- legs, knock- knees can cause pronounced disability. Long- term effects on skeletal health can occur with reduced bone size and mass predisposing to osteoporotic fracture later in life (Elder& Bishop, 2014).

Rickets can be classified broadly as calcipenic or phosphopenic. While the skeletal findings are similar for both, the extraskeletal manifestations of rickets vary depending upon the primary mineral deficiency (Caetano et al., 2012).

Calcipenic rickets is often associated with low serum calcium levels, while phosphopenic rickets is characterized by low serum levels of phosphorus. Calcipenic rickets is caused by calcium deficiency, which is usually due to insufficient intake or metabolism of vitamin D, or in some cases due to inadequate intake or absorption of calcium (Misra et al., 2008) and (Sahay& Sahay, 2012). Phosphopenic rickets is usually caused by renal phosphate wasting (Sahay& Sahay, 2013). There is another group of disorders that are not considered classic forms of rickets but in which mineralization is inhibited and thus rachitic features occur. Examples include hypophosphatasia and fluoride toxicity (Rajah et al., 2011).

Although nutritional rickets is the most common type of this disease, there are several other forms, including genetic disorders of vitamin D metabolism or phosphate transport. Although rare, hereditary hypophosphataemic rickets is the most common form of heritable rickets (Caetano et al., 2012).

Genetic Disorders of Vitamin D Metabolism include Pseudovitamin D deficiency rickets (PDDR): (OMIM 264700), also referred to as Vitamin D dependent rickets type I (VDDR- I) or Vitamin D 1 α - hydroxylase deficiency rickets, is a rare hereditary autosomal recessive disorder caused by mutations of the 1 α - hydroxylase gene. Characteristic laboratory features are hypocalcemia, increased serum concentrations of parathyroid hormone (PTH), and low or undetectable serum concentrations of 1, 25(OH)₂D despite normal or increased concentrations of 25,OH₂D (Kim, 2011).

A number of mutations have been found in the 1 α - hydroxylase gene (CYP27B1) gene including missense mutations, deletions, duplications and splice site mutations in patients with VDDR- I (Kim et al., 2007) and (Malloy& Feldman, 2010).

Presentation of rickets is in the toddler age. Treatment is with 1,25-dihydroxycholecalciferol (alfacalcidol or calcitriol) in the dose range of 0.5- 2.0 μ g/ Day (Ramasamy, 2008).

Hereditary vitamin D- resistant rickets (HVDRR) (OMIM 277440) Also known as vitamin D dependent rickets type II (VDDR II), is an autosomal recessive disease with alopecia in 50% of cases. It is caused by mutations in the gene for the vitamin D receptor (VDR) with resistance to the action of the active metabolite and therefore patients show very high levels of 1,25(OH)₂D₃, distinguishing this condition from PDDR. Treatment is more difficult, as although some patients may respond to high- dose alfacalcidol, many require intravenous calcium infusions via a central line to heal the rickets (Pai& Shaw, 2011).

Hypophosphatemic Rickets, Hypophosphatemic rickets (HR) or vitamin D- resistant rickets is a group of renal phosphate wasting disorders including X- linked dominant hypophosphatemic rickets (XLH) (OMIM 307800) which is the most common form of heritable rickets (Whyte and Thakker, 2013) caused by inactivating mutations in PHEX, a gene located on Xp22.1, autosomal dominant hypophosphatemic rickets (ADHR, OMIM 193100) due to gain- of- function mutation in FGF23 gene, autosomal recessive hypophosphatemic rickets (ARHR, OMIM 241520) due to homozygous or compound heterozygous mutations involving the DMP1 or ENPP1 genes and hypophosphataemic rickets with hypercalciuria (HRH) (OMIM 241530) caused by mutation within the SLC34AC gene encoding the Type IIc sodium-phosphate co- transporter (Lorenz- Depiereux et al., 2006).

Hypophosphatemic rickets result from defects in renal tubular reabsorption of phosphate, and share similar clinical and biochemical features such as bone deformity, bone pain, short stature, poor dental development, hypophosphatemia, and inappropriately normal serum 1, 25(OH)₂D level (Amatschek et al., 2010).

Treatment of hereditary rickets aims to correct or minimize rickets/ osteomalacia, radiographic abnormalities, and skeletal deformities, decreases the number of necessary surgeries, and improves adult height. Early initiation of treatment appears to optimize height outcomes. In this study we aimed at the proper diagnosis and evaluation of the effect of treatment of different types of hereditary rickets over 2 years.

Patients And Methods:

This descriptive and prospective study included 13 Egyptian children (9males and 4females) with hereditary rickets who were recruited from the Limb Malformations and Skeletal Dysplasia Clinic (LMSDC), Medical Centre for Scientific Excellence, National Research Centre (NRC) from January 2010 to December 2012. They were selected based on clinical, radiological manifestations of rickets and laboratory findings including serum calcium, phosphorous, alkaline phosphatase and parathormone hormone in addition to creatinine level. Selected patients were classified into 4 patients with calcipenic and 9 patients with phosphopenic rickets and received medications accordingly.

Calcipenic rickets patients: were treated with both activated vitamin D (calcitriol or alfacalcidol) and high doses of elemental calcium in oral form because of difficult application of intravenous calcium as a long term therapeutic approach due to difficulty of continuous canulations or caring about central line. We started treatment with calcitriol at a dose of 1 μ /day and calcium supplements at 500mg elemental dose. The doses were gradually elevated in those resistant to the initial doses.

Phosphopenic rickets patients: were treated with both calcitriol and phosphate. Phosphate dosages were titrated to minimize abdominal pain or diarrhea, till reaching target doses. As most treatment studies has no consistent reports regarding optimal doses and concerns regarding the side effects (Fujiwara et al., 2013); we started the treatment regimen with an elemental phosphorus dose of 30mg/kg/day (in 3 to 5 divided doses) and calcitriol at dose of 0.5 μ / Kg/ Day

Assessment every 6 months included growth parameters, clinical improvement in rachitic manifestations and bony deformities, radiologic abnormalities and laboratory follow up by serum calcium, phosphorus and alkaline phosphatase. Also serum creatinine was done to monitor renal

function. Parathormone hormone could not be done in most cases because of the high cost of the laboratory tests and the medications used.

Statistical Analysis:

Statistical analysis has been done using SPSS version 18. Descriptive statistics were done for numerical parametric data as median and inter-quartile range, while they were done for categorical data as number and percentage. Inferential analyses were done for quantitative variables using Mann whitney U in cases of two independent groups with non parametric data and Wilcoxon signed rank test in cases of two dependent groups with non-parametric data. Inferential analyses were done for qualitative data using Chi square test for independent variables and Fisher exact test for independent variables with small expected numbers as well as McNemar test for paired categorical data. While correlations were done using Spearman's rho test for numerical non parametric and categorical data. The level of significance was taken at P value <0.050 is significant.

Results:

Thirteen children with hereditary rickets were studied, with a median age at presentation of 3 years (IQR 2.0- 4.3 and range 16 months- 18 years) four of which were calcipenic (30.8%) and nine cases were hypophosphatemic rickets (69.2%). Their demographic data are presented in table (1) and figure (1).

Four patients with calcipenic rickets received high doses of oral calcium and active form of vitamin D (calcitriol). One of them showed clinical improvement in pain, deformities and decrease thickening and broadening of joints giving the diagnosis of 1 α - Hydroxylase Deficiency (vitamin D dependent rickets type I (VDDR I), however the other 3 patients were resistant to treatment and one of them had alopecia totalis with the most severe clinical phenotype giving the diagnosis of Hereditary vitamin D- resistant rickets (HVDRR).

Nine patients had hypophosphatemic rickets. They had hypophosphataemia and increased alkaline phosphatase with normal calcium. They were treated with calcitriol at dose of 0.5 μ / Kg/ Day and oral phosphorous. Phosphorous dosages were titrated and divided in four to five doses to minimize abdominal pain or diarrhea, till reaching target doses 40mg/ Kg/ Day and also to insure adequate absorption.

Improvement in bony pains and rachitic manifestations was noted in all patients but no improvement was detected in growth in the short cases.

Table (2) and figure (2) show that Height standard deviation (SD) decreased at follow- up1 (FU1) then increased beyond basal level, but differences were statistically non- significant.

Table (3) and figure (3) show that the frequency of high alkaline phosphatase levels non- significantly decreased at FU1 then re- increased at FU2.

Table (1) Demographic statistics of patients with hereditary rickets

		Median (IQR)	Range
Age (Years)		3.0 (2.0- 4.3)	1.0- 18.0
		N	%
Sex	Male	9	69.2
	Female	4	30.8
Parental Consanguinity	Yes	6	46.2
	No	7	53.8
Type	Calcipenic	4	30.8
	Phosphopenic	9	69.2

IQR: inter- quartile range, N: number

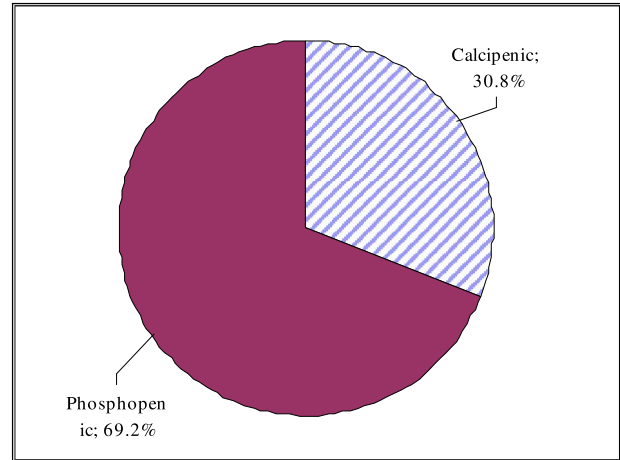


Figure (1) Percentage of different types of hereditary rickets in the studied group of patients
Height SD before and after treatment in patients with hereditary rickets is shown in tables (2) and figures (2).

Table (2) Height SD before and after treatment in rickets patients

Time	N	Median (IQR)	Range		
Basal	13	- 3.0 (- 3.9- -2.1)	- 8.0- -0.6		
Fu1	12	- 2.6 (- 3.5- -2.0)	- 4.8- -1.0		
Fu2	7	- 3.7 (- 4.8- -3.0)	- 5.4- -2.6		
Difference Between Times #					
Times	N	Median (IQR)	Range	z	p
Basal/ Fu1	12	- 0.1 (- 0.4- 0.2)	- 1.0- 1.8	- 0.236	0.814
Basal/ Fu2	7	- 0.1 (- 2.0- 0.4)	- 2.4- 0.5	- 1.014	0.310
Fu1/ Fu2	7	- 0.9 (- 1.4- 0.0)	- 1.8- 0.2	- 1.753	0.080

#Negative values indicate reduction, z: Wilcoxon signed rank test, *Significant

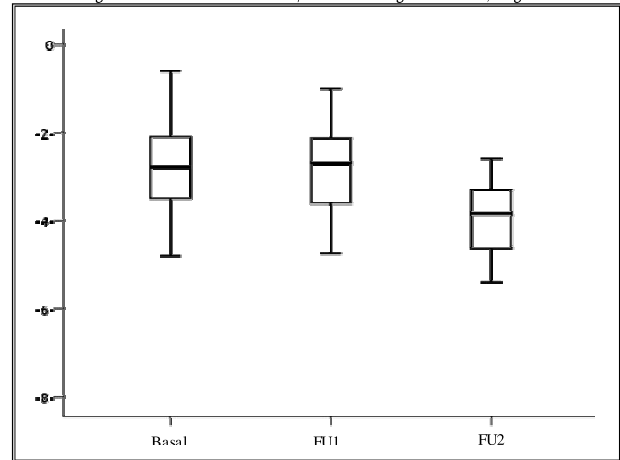


Figure (2) Height SD before and after treatment in rickets patients (Box and Whisker plot)

Table (3) Serum Alkaline phosphatase level before and after treatment in rickets cases

Time	N	High	Normal
Basal	13	11 (84.6%)	2 (15.4%)
Fu1	13	7 (53.8%)	6 (46.2%)
Fu2	11	6 (54.5%)	5 (45.5%)
Difference Between Times #			
Times	N	Improvement	P
Basal/ Fu1	13	- 30.8%	0.125
Basal/ Fu2	11	- 30.1%	0.250
Fu1/ Fu2	11	0.7%	1.000

#Negative values indicate reduction, ^McNemar test, *Significant

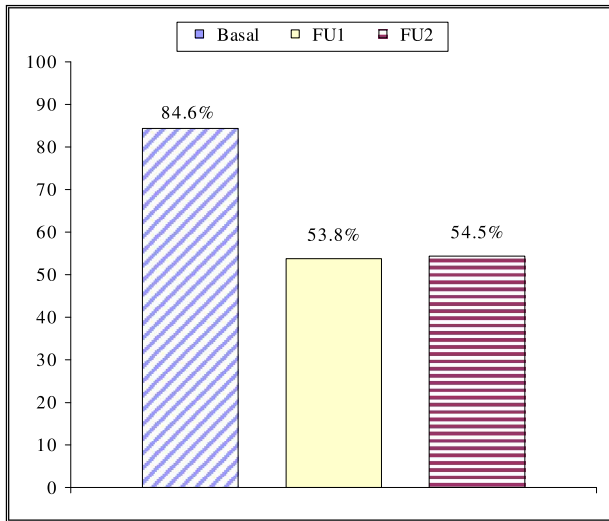


Figure (3) Frequency of high serum alkaline phosphatase before and after treatment in rickets cases

Discussion:

Hereditary rickets (HR) can be classified into two major groups: calcipenic and phosphopenic rickets. The present study included only 13 children with HR over 2 years of study, reflecting the rarity of the disease. Another study by Caetano et al. (2012) reported 11 patients with hypophosphataemic rickets over a period of 10 years.

The median age at presentation was 3 years (IQR 2.0- 4.3), with range varying from 16 months to 18 years. They all had bony pains, skeletal deformities in the form of bowing of legs and broad thickened wrists and ankles as well as frontal bossing. Delayed closure of the anterior fontanelle was noted only in 2 patients who were 12& 16 months of age at presentation, others were older and this could not be reported from their mothers. Rosary beads and pigeon chest were evident in the first 3 patients who proved with laboratory results to have calcipenic rickets. Only one patient had alopecia totalis with severe skeletal deformities.

All studied patients with HR had severe dental caries, enamel hypoplasia and delayed teeth eruption reflecting failure of teeth mineralization but none of our cases had teeth abscesses although this was reported to be common particularly in hypophosphatemic rickets (Malloy et al., 2005) and (Drezner, 2006).

The characteristic rachitic manifestations on x- rays of wrists, knees and ankles, with widening of the physal plates and cupping and fraying of the adjacent metaphysis were seen in all patients.

Four patients had calcipenic rickets with hypocalcemia and elevated alkaline phosphatase. They all exhibited secondary hyperparathyroidism with markedly elevated parathyroid hormone (PTH) levels. A history of positive consanguinity reflecting autosomal recessive inheritance pattern was present in all cases. Molecular analysis was not available and diagnosis was based on the clinical picture and response to treatment.

We started treatment for these four patients with physiologic doses of calcitriol (1 α - hydroxyvitamin D_{0.05} μ /kg/day) and calcium except for the patient with alopecia, who had severe skeletal deformities and bony pains with history of previous treatment with high doses of cholecalciferol without improvement. This patient received very high doses of calcitriol and calcium and the doses were raised progressively without significant improvement denoting defective interaction between calcitriol and receptor and confirming

the diagnosis of hereditary vitamin D- resistant rickets (HVDRR) with alopecia. Improvement was only noted in bony pains. Out of the other 3 patients with calcipenic rickets, one patient showed improvement and normalization of serum calcium and alkaline phosphatase after 6 months, normalization of phosphorous and parathormone after 9 months and there was improvement in height from- 4.2SD to- 2.4SD after 1 year. So with good response to 1 α - hydroxyvitamin D the patient was diagnosed as 1 α -Hydroxylase Deficiency (vitamin D dependent rickets type I (VDDR I) PDDR. Two patients without alopecia had severe rachitic manifestations without improvement with physiologic doses or progressively rising high doses of calcitriol and calcium supporting the diagnosis of hereditary vitamin D- resistant rickets (HVDRR) without alopecia. The maximum dose reached in patients with HVDDR and HVDRR was 30 μ of calcitriol and 1500mg of elemental calcium.

The treatment protocol for patients with HVDRR is not standardized. Several reports describe intravenous calcium therapy to achieve normal serum calcium levels and healing of the rickets (Hochberg et al., 1992) and (Ma et al., 2009). There were also limited publications regarding the effectiveness of oral calcium therapy (Hochberg et al., 1992) and (Wong et al., 1994).

The main problem with treatment in these patients was non- compliance due to the oral daily multiple dose regimens, the financial burden, the unavailability of the medications in some instances and the limited benefit noticed. In addition to the frequent follow up laboratory investigations including kidney functions to rule out any renal insult from the high doses of the calcitriol.

The second group of HR in this study included nine patients with phosphopenic rickets (69.2%). These patients had hypophosphataemia and increased alkaline phosphatase with normal calcium. They all had history of positive consanguinity suggesting autosomal recessive inheritance pattern. One patient had another similarly affected cousin, offspring of consanguineous parents supporting the possibility of AR hypophosphatemic rickets. However, 2 affected sisters with an affected father raise the possibility of X- linked dominant hypophosphatemic rickets (XLH) being also the most common type of hereditary hypophosphatemic rickets as reported by Roth et al. (2009).

Genetic studies are the most recent tool to diagnose rickets. Although very helpful confirming the disease, they are expensive and not easily available worldwide (Caetano et al., 2012). None of our cases had molecular diagnosis due to unavailable facilities in the meantime. All patients with hypophosphatemic rickets had bone deformities mainly bowing of legs with genu valgum, bony pain and broad wrists and ankles. Growth retardation was present in all except two (patients 10& 11), the oldest patient presented to us with severe short stature (height:-8.0 SD). Bone deformities sometimes required surgery for correction.

Although all patients had hypophosphatemia and elevated alkaline phosphatase, laboratory values varied depending on the stage of the disease and previous medication, explaining the different results in our study.

All patients with hypophosphatemic rickets received active vitamin D and oral phosphate that was divided on several daily doses to insure adequate absorption and minimize the side effects. Doses were adjusted based on the laboratory follow up results.

Improvement in bony pains and rachitic manifestations was noted but no improvement was detected in growth in the short cases. Two patients

developed secondary hyperparathyroidism after previous normal parathormone level denoting over treatment with phosphate so the dose of phosphate was decreased.

No information is available concerning the most effective dose of phosphate and how many times it should be administered in the treatment of patients with hypophosphatemic rickets (Fujiwara et al., 2013). In pediatric endocrinology and inborn errors of metabolism, 40- 100 mg/kg/d, divided into 4 to 6 doses, is recommended. However, adherence tends to become poor when short intervals are selected (Roth et al., 2009).

Patient compliance was the major problem as with calciopenic rickets as in addition to the previously reported problems with drug intake, oral phosphate preparation has a bad taste, results in gastric discomfort and diarrhea and the buffer is only prepared at a specific pharmacy at Abou- Elrish Hospital which made it difficult to obtain for those living in different governorates.

The criteria for adjusting the dose of active vitamin D or phosphate buffer were various. One problem is that both serum phosphate and ALP values are age dependent, and normalization of serum phosphate levels and ALP was difficult. X- ray findings are not quantitative, and growth is long term. Thus, these indices are difficult to use in the short term. It is also critical to avoid side effects of the treatment. Thus, the doses of active vitamin D and phosphate should be reduced when hypercalciuria and secondary hyperparathyroidism are observed, respectively (Fujiwara et al., 2013).

Treatment with phosphate supplements and 1 α vitamin D derivatives heals active lesions of rickets, but does not normalize growth of XLH patients. Patients might benefit from recombinant human growth hormone (rhGH) therapy, which may accelerate the growth rate without increasing body disproportion or correcting hypophosphatemia. These clinical data as well as research findings obtained in Hyp mice suggest that the pathogenesis of defective growth in XLH and other hypophosphatemic syndromes is not entirely dependent on the mineralization disorder and point to other effects of hypophosphatemia itself or fibroblast growth factor 23 (FGF23) on the metabolism of bone and growth plate (Santos et al., 2013).

At present, there is no curative therapy for hereditary rickets, and active vitamin D and phosphate are administered to correct hypophosphatemia and elevation of ALP (Kienitz et al., 2011). However, normalization of the serum phosphate concentration is difficult due to elevation of FGF23, leading to increased excretion of phosphate into urine (Imel et al., 2010, Carpenter et al., 2010). Insufficient treatment is associated with growth retardation (Quinlan et al., 2012). On the other hand, over treatment with phosphate leads to secondary hyperparathyroidism, and large doses of active vitamin D increase the risk of hypercalciuria (Carpenter et al., 2011). Though a recommendation for treatment of hereditary rickets has been published, it is far from complete cure.

Establishing an early diagnosis of these genetic forms of rickets is challenging, especially in developing countries where nutritional rickets (NR) is the most common variety of the disease. A prompt diagnosis is necessary to initiate adequate treatment, resolve biochemical features and prevent complications, such as severe deformities that may require surgical intervention (Donghi et al., 2011).

Indeed the diagnosis should be considered in any child presenting with angular deformity of the limbs and delayed growth (McBride et al., 2007). Without a correct diagnosis, early and perhaps inappropriate major surgery is

doomed to failure. The goals of treatment are to prevent or correct limb deformity before skeletal maturity and to achieve optimal height (Whyte, 2002).

In conclusion, hereditary rickets are rare group of metabolic bone disorders with significant long- term morbidity. They should be suspected in children presenting with short stature, developmental delay and orthopedic abnormalities with increased alkaline phosphatase, low serum phosphorus or calcium which confirm the diagnosis. Early diagnosis, supported by molecular studies and treatment are essential to minimize morbidity in children.

References:

- Amatschek S, Haller M& Oberbauer R. Renal phosphate handling in human- what can we learn from hereditary hypophosphataemias?" *Eur J Clin Invest.* 2010; 40: 552- 560.
- Caetano JS, Cordinha C, Gomes C& Correia AJ. Hereditary hypophosphatemic rickets: experience from a paediatric nephrology unit. *Port J Nephrol Hypert.* 2012; 26: 278- 284.
- Carpenter TO, Imel EA, Holm IA, Jan de Beur SM, Insogna KL. A clinician's guide to X- linked hypophosphatemia. *J Bone Miner Res* 2011; 26:1381- 1388.
- Carpenter TO, Insogna KL, Zhang JH, Ellis B, Nieman S, Simpson C, et al. Circulating levels of soluble klotho and FGF23 in X- linked hypophosphatemia: circadian variance, effects of treatment, and relationship to parathyroid status. *J Clin Endocrinol Metab* 2010; 95: 352- 357.
- Craviari T, Pettifor JM, Thacher TD, Meisner C, Arnaud J, Fischer PR, for the Rickets Convergence Group. Rickets: an overview and future directions, with special reference to Bangladesh. *J Health Popul Nutr.* 2008; 26: 112- 121.
- Donghi V, Di Frenna M, di Lascio A, Chiumello G& Weber G. Vitamin D dependent rickets, diagnostic and therapeutic difficulties: two case reports. *J Pediatr Endocrinol Metab.* 2011; 24:801- 805.
- Drezner MK. Osteomalacia and Rickets. In Seibel MJ, Robins SP& John P(eds). *Dynamics of Bone and Cartilage Metabolism* (Second Edition). 2006: 739- 754.
- Elder CJ& Bishop NJ. Rickets. *Lancet* 2014. Published online January 10, 2014 [http://dx.doi.org/10.1016/S0140-6736\(13\)61650-5](http://dx.doi.org/10.1016/S0140-6736(13)61650-5)
- Fujiwara M, Namba N, Ozono K, Arisaka O, Yokoya S& Committee on Drugs, Japanese Society for Pediatric Endocrinology. Treatment of Hypophosphatemic Rickets with Phosphate and Active Vitamin D in Japan: A Questionnaire- based Survey. *Clin Pediatr Endocrinol.* 2013; 22: 9- 14.
- Hochberg Z, Tiosano D, Even L. Calcium therapy for calcitriol- resistant rickets. *J Pediatr* 1992;121:803- 808.
- Imel EA, DiMeglio LA, Hui SL, Carpenter TO, Econs MJ. Treatment of X- linked hypophosphatemia with calcitriol and phosphate increases circulating fibroblast growth factor 23 concentrations. *J Clin Endocrinol Metab.* 2010; 95: 1846- 1850.
- Kienitz T, Ventz M, Kaminsky E, Quinkler M. Novel PHEX nonsense mutation in a patient with X- linked hypophosphatemic rickets and review of current therapeutic regimens. *Exp Clin Endocrinol Diabetes* 2011; 119:431- 435.
- Kim CJ, Kaplan LE, Perwad F, Huang N, Sharma A, Choi Y, et al.